



Overview of Cementless Stems in Total Hip Arthroplasty – Review Paper on the Corail Style Stem

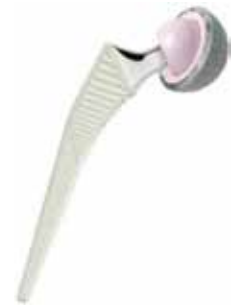Christian Wright, B.S*., Declan Brazil, PhD*,** and Timothy McTighe, Dr. HS (hc)**

Abstract:

The review summarizes published literature from a range of reputable sources regarding hip prosthesis (stems) of a specific design style (Corail) used currently in cementless Total Hip Arthroplasty.

The short-term results of the best cementless femoral components recorded in the Norwegian Arthroplasty Register as described by Havelin et al, include the Corail, IMT, Profile and Zweyuller stems with revision for loosening <1% at 4.5 years, compared to cemented counterparts.

The critical review of published studies shows equivalence of the predicate Corail stem to the Signature CL2 femoral stem in all critical characteristics is demonstrated to represent the likely clinical performance of the CL2 stem implanted. This is using modern surgical techniques without cement.



Introduction:

Since the introduction of cementless THR in the 1970s femoral and acetabular components have undergone substantial changes and a range of design philosophies have demonstrated variable clinical success with some notable failures to meet design intent.

However, many surgeons have reported excellent intermediate to long-term results associated with the use of tapered stems inserted without cement during primary total hip arthroscopy from 1984 onwards. With an endpoint of aseptic loosening of the stem, excellent survivorship figures have been quoted of up to 99.1% at 10 years although specific details of calculations have not always been included in the published data. One of the most widely used cementless tapered stem is the fully hydroxyapatite coated titanium Corail stem in combination with a variety of acetabular components that will be included in this review.

Materials and Methods:

IDENTIFICATION OF DATA

For each section of the clinical review the data sources for systematic review will be provided. The following are typically data sources that were considered acceptable:

- medical and paramedical databases
- technical papers from relevant Standards Committees
- “grey literature” (theses, internal reports, non peer review journals, the internet, industry files)

* Signature Orthopaedics, NSW, Australia

** Joint Implant Surgery and Research Foundation
Chagrin Falls, OH
Non-Profit Founded in 1971
www.jisrf.org



For all the clinical review of the performance of predicate or similar devices the following journals have been selected as source data:

- Journal of Arthroplasty
- Clinical Orthopaedics and Related Research
- Journal of Bone and Joint Surgery (British and American)
- Journal Reconstructive Review

Additionally, the following inclusions criteria were used in selecting appropriate clinical data for the file:

- Publications in English
- All patient populations

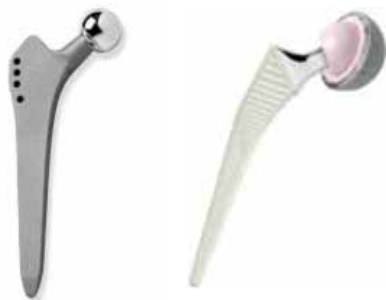The following exclusion criterion was used for clinical data for file:

- In vitro studies

Review:

Various porous coated, grit or sand blasted, bead-sintered or plasma-sprayed surfaces on the femoral component have been utilized in cementless THA and there remains some differences in opinion as to the most effective coating for mechanical stability of the implanted stem that promotes bone ingrowth and achieves long term clinical performance outcomes to at least equivalent to that of the well established cemented stems.

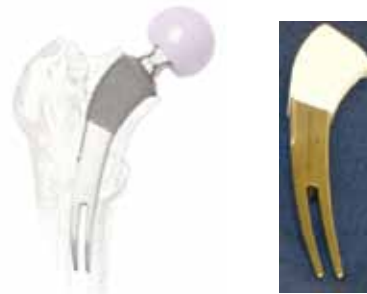Examples Of Cementless Surface Coatings For THA



Matte Surface Finish / HA Fully Coated

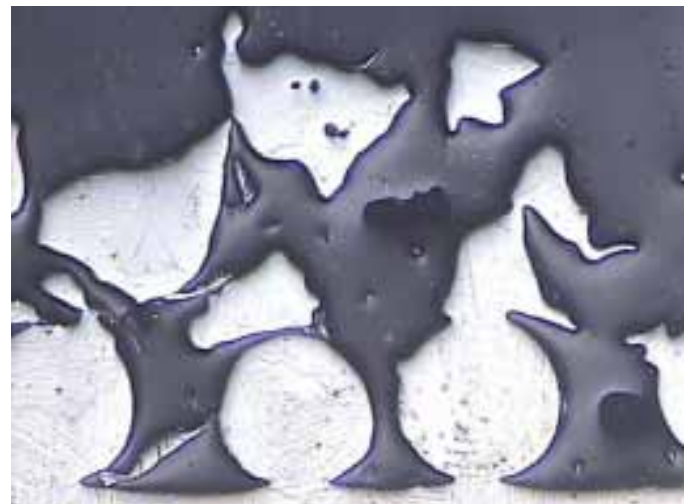


Titanium Plasma Spray / Sintered Porous Beads




Hybrid Coating HA over Plasma Titanium Spray

Cross Sectional Views of Surface Coatings




Particle Sintered Coating

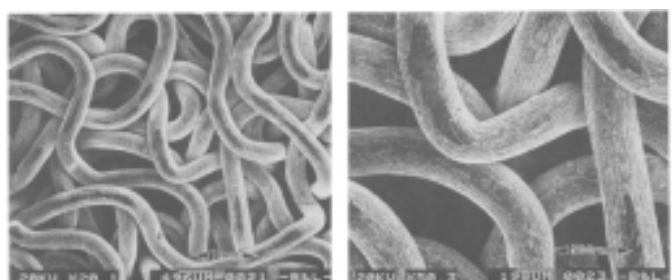


Porous Sintered Coating

SEM Images




Cross Section



Porous Sintered Wire

SEM Images



Cross Section



Hydroxyapatite (HA) Plasma Spray

Hydroxyapatite (HA) is a naturally occurring mineral found in bone and tooth enamel comprising Calcium and Phosphate in a ratio of 1:1.67. It is unique in its biocompatibility and has been clearly established to be non toxic, non allergenic and non-inflammatory. Ions released from HA coatings have not been shown to have any detrimental effect on the surgical outcome associated with wear debris. Rokkum et al 1999¹ biopsied 20 hip interfaces up to

eight years post operatively and found no evidence of HA particles at a site distant from the bone implant surface.

The Arthro group² report on the first 12 years of use of the *Corail* prosthesis from 7800 THA surgeries carried out from 1986-1998 across an almost Gaussian curve for age distribution of patients from 16 to 104 years old with a mean age of 62 years with 70% of patients indicated with primary osteoarthritis of the hip. It was noted that HA-coated stem performed well in fractures of the femoral neck in the elderly patients and in revision cases associated with septic conditions. No cases of aseptic loosening of the stem were recorded. A reduced incidence of thigh pain has been observed with use of this stem and 63% of patients from this study were pain free with normal motion and function at final follow up. Superior benefits of a HA coating are claimed to provide biological fixation of the prosthesis as well as maintain a living bone bed ensuring long term stability of the implant and the ability to resist infection.

Varying thickness, porosity & crystallinity of HA coatings have been utilized by manufacturers and the *Signature CL2 (N.S. Whales, AU)* and our predicate, the *Corail (DePuy)* stem has a coating thickness of 155 µm. The thickness of HA coating applied to cementless femoral stems ranges from 50-200 µm with the intention of achieving early fixation of the stem by osteointegration with the bone interface.

The favourable clinical performance of the *Corail* stem after 12-15 years is well documented by the Arthro group^{2,9} who demonstrated from longer term radiolucency studies that HA also has a role in long term stem fixation and the thickness of the coating probably plays a role. No lucent lines were observed in their studies that could suggest disruption between implant and bone. The coating technology is reproducible and HA debris has not been linked to any specific early component failures in THA.

RSA studies have been used to demonstrate that HA-coated prostheses are significantly more stable than porous coated implants³: pp 171-207: Geesink R.G.T. The “perfect” ingrowth of the HA-coated stem, however, is difficult to extract in revision surgery and some osteolysis has been observed to occur. Delamination of the coating is not considered relevant for the coating thickness of the *Corail* stem⁹.

Many short term animal studies conducted on HA-coated stems³ have established clear short term benefits of the osteoconductive properties of HA and its ability to achieve bone ingrowth under dynamic load and across a gap around the press-fit stem and bone compared to porous coated titanium stems³; pp 107-130; Soballe K et al. Clinical outcomes at 5 years indicate a significant improvement in patient satisfaction, particularly with absence of pain compared to other cemented/ cementless implants.

Data from longer term studies is now available and favourable survivorships have been cited for the **Corail** stem of 97.7% - 99.2% @ 10years^{2,4} as compared to survivorship of the Biomet Integral stem of 98% @ 10 years⁵ and **Zweymüller** of 96.4% @10years⁴.

Stem	% Change in Bone Density ("Calcar" region)
Zwey-Muller (Ti-6Al-4V matt surface)	24
Corail (Hydroxyapatite fully coated Ti-6Al-4V)	8.0
Optifix (Ti-6Al-4V) proximal only porous coated	14.8
Autophor 900S (Co-Cr alloy- microporotic surface)	18.5

The Norwegian arthroplasty register prospective observational study⁴ incorporated a broad range of hip prosthesis marketed between 1987 and 2005 and draws on 13,760 cementless THRs representing 13% of total hip surgeries during this period. The **Corail** stem was used in 39% of the cementless THR and the Kaplan-Meier score for 15 year survivorship of 97% with a mean patient age of 54 years are excellent. Its performance against an endpoint of revision for any reason was marginally better than **Zweymüller**, **Filler**, **Taparloc** and **Omnifit** stems that still gave acceptable KM Survivorship figures of greater than 90% at 10 years suggesting that a number of stem design philosophies allow good performance in regard to femoral fixation.

Problems other than loosening such as: thigh pain, femoral osteolysis, stem-derived instability, dislocation and peri-prosthetic fractures were also cited as important failure modes of these stems. The overall survival of cementless THR was rated as poor from this study due to the high number of revisions for the failure of the acetabular bearing surfaces and liners.

Chambers et al 2007⁶ said on the success of cementless fixation being attributed to firstly the tapered stem geometry of the Corail stem. Why its self-locking property with variable amounts of subsidence described and secondly to the use of HA coating in superior proximal femoral osseointegration. Reduced subsidence risk and better preservation of peri-prosthetic bone quality reflected radiographically by less proximal stress shielding and superior osseous remodelling around the implant proximally.

Component malpositioning has been noted to be associated with higher failure rates of cementless THA particularly when varus. From a consecutive series of 98 arthroplasties performed with a cementless tapered-wedge stem at a mean follow-up of 7.7 years, Min et al 2008⁷, did not find any difference in Harris Hip score values of patients or prevalence of thigh pain in a distribution of stem positions evaluated to be in neutral (63%); valgus (21%) and varus (16%) position. Hence they concluded that a varus stem position did not adversely affect fixation durability or clinical outcome.

Vidalain 2004⁸ claims that extraction of a well integrated HA coated femoral implant is always possible through a transfemoral approach. This option minimizes additional bone sacrifice and the reconstruction of the femoral shaft around a new stem is considered to be a straight forward, easily performed procedure.

Karachalios et al 2004⁹ carried out a 10 year randomized study on four different cementless stems in regard to the clinical relevance of stress shielding and calcar atrophy known to be a consequence of THR. The authors attribute the etiology of periprosthetic bone loss to two predominant factors, first to "stress shielding" of the proximal femur as a result of changes in loading pattern after implant and secondly to osteolysis

due to presence of polyethylene wear debris. Bone density in Gruen zone 7 (directly under the stem neck proximally, “Calcar” region) is cited as the region of highest bone loss. The table below shows the percentage bone density lost reported by these authors after 2 years associated with commonly implanted stems.

However, progressive recovery of bone density observed after 3 years was demonstrated to continue until almost to baseline values after 10 years. The authors therefore conclude that the phenomenon of stress shielding may have been overestimated in earlier publications considering only early to medium term post operative bone density results [9] as in this longer term study, bone has been observed to adapt its remodelling process to non physiological loading.

Vidalain 2004⁸ observing only the clinical performance of the *Corail* stem over a 15 year period records a rate of 0.4% cases (out of 243 > 10 years) of major stress shielding. The author tracked bone density loss in several zones around the implanted stem for a period of 5 years and up to 49.9% loss (21.9% loss @ 3 months) was recorded in the Calcar zone in a series of 42 patients post cementless THR. Prevalence of stress shielding is increased in women due to pre-op osteopenia, femoral neck fracture or wide femoral canal. Equilibrium and static bone density was reached after 5 years within this study and the extent of bone loss was associated with increasing female age possibly also with osteoporosis. Implant size was also cited to affect proximal bone loss after THR.

Currently, cementless fixation has become preferred for revision hip arthroplasty. Failure rates for cups are typically three times higher than stem loosening with reported rates from 39-58 %¹⁰. Revision due to liner wear and pelvic osteolysis is also common.

Bone loss and suboptimal fixation to deficient bone remain challenges for successful clinical outcomes across all indications for use in THA. Modern post surgical management strategies such as local administration of magnesium hydroxide around the bone implant interface have been reported to be beneficial for retention of bone mass in patients with osteoporosis¹⁰.

Timely administration of peri-operative antibiotic prophylaxis has reduced infection rates significantly

over the past 5 years. Ritter et al¹¹ determined the infection rate from total hip arthroplasties from a single surgeon over a 19 years period to 2005 was only 1.77%. A US cohort of 3346 cementless primary THAs carried out during the period 1987-2007 yielded post operative peri-prosthetic femoral fracture rate of 1.2%.

Clinical data as it becomes available for the *Signature CL2* stem will be evaluated and monitored according to our post market plan including RSA studies for performance and safety in clinical use from centres in Australia after market release.

The *Signature* cementless hip prosthesis range is anticipated to have a reliable, safe clinical performance to at least equivalent to the well established predicate devices discussed in this and related reports since our range has adopted and consolidated the most critical of their design and performance features.

References

1. Røkkum M, Brandt M, Bye K, Hetland KR, Waage S, Reigstad A. Polyethylene Wear, Osteolysis and Acetabular Loosening With an HA-Coated Hip Prosthesis: A Follow-Up of 94 Consecutive Arthroplasties J Bone Joint Surg 1999;81-B:582-9
2. Vidalain JP, ARTRO group. The Corail System in Primary THA: Results, Lessons and Comments From the Series Performed by the ARTRO Group (12-Year Experience) European Journal of Orthopaedic Surgery & Traumatology 1999;9:87-90
3. Geesink GT and Manley MT. Hydroxylapatite Coatings in Orthopaedic Surgery 1993, Raven Press Ltd New York
4. Hallan G, Lie SA, Furnes O, Engesaeter LB, Vollset SE, Havelin LI. Medium- and long-term performance of 1 516 uncemented primary femoral stems from the Norwegian arthroplasty register J Bone Joint Surg [Br] 2007;89-B:1574-80
5. Marshall AD, Mokris JG, Reitman RD, Dandar A, Mauerhan DR. Cementless Titanium Tapered-Wedge Femoral Stem: 10- to 15-Year Follow-Up J Arthroplasty 2004;19(5):546-552
6. Chambers B, St. Clair SF, Froimson MI. Hydroxyapatite-Coated Tapered Cementless Femoral Components in Total Hip Arthroplasty J Arthroplasty 2007;22(4-1):71-3
7. Min BW, Song KS, Bae KC, Cho Ch, Kang DH, Kim SY. The effect of stem alignment on results of total hip arthroplasty with a cementless tapered-wedge femoral component. J Arthroplasty. 2008;23:418-23
8. Vidalain JP. Corail Stem Long Term Results Based on the 15-year Arthro Group Experience in Epinette JA and Manley MT. Fifteen years of Clinical Experience with Hydroxyapatite Coatings in Joint Arthroplasty, Springer- Verlag France, 2004; pp 217-223
9. Karachalios T, Tsatsaronis C, Efraimidis G, Papadelis P, Lyritis G, Diakoumopoulos G. The Long-Term Clinical Relevance of Calcar Atrophy Caused by Stress Shielding in Total Hip Arthroplasty A 10-Year, Prospective, Randomized Study, J. Of Arthroplasty 2004; 19(4), 469-75
10. Huo HM, Parvizi JB, Bal S and Mont MA. What's New in Total Hip Arthroplasty J Bone Joint Surg Am. 2008; 90:2043-205
11. Ritter MA, Olberding EM, Malinzak RA. Ultraviolet lighting during orthopaedic surgery and the rate of infection. J Bone Joint Surg Am. 2007;89:21953-1940.



**I CAN GO TO ANY HOSPITAL
TO PERFORM ORTHOPEDIC SURGERY.**

**I CHOOSE ST. VINCENT CHARITY
MEDICAL CENTER**



As an orthopedic surgeon in Cleveland, I'm grateful to practice medicine in an area with exceptional healthcare. But I choose the Spine and Orthopedic Institute at St. Vincent Charity Medical Center. They're one of the highest-ranked orthopedic hospitals in the nation. I wouldn't settle for anything less. You shouldn't either.

— Louis Keppler, M.D.

SPINE AND
ORTHOPEDIC INSTITUTE
ST. VINCENT CHARITY MEDICAL CENTER

To schedule an appointment, call 877.98.SPINE
or visit us at stvincentcharity.com.

John S. Collis, M.D. | Louis Keppler, M.D.
Deborah A. Blades, M.D. | Young H. Kim, M.D.
Joel D. Siegal, M.D. | D. Philip Stickney, M.D.
Matthew Levy, M.D.

A Ministry of the Sisters of Charity Health System