



The Fate of the PCL in Cruciate Retaining TKA A Critical Review of Surgical Technique

Sherif M. Sherif, M.D.†, Matthew V. Dipane, B.A.†, Edward J. McPherson, M.D., FACS†

Abstract

This study prospectively reviews 368 consecutive primary TKA's, documenting the status of the PCL during 3 stages of the TKA procedure: 1) at initial arthrotomy, 2) after all bone cuts were made, and 3) after final balancing with all components in place. We found at initial presentation that 94% of PCL's were intact. After the bone cuts were made only 51% of PCL's remained intact. Finally, after knee balancing and all implants were in place, only 33% of PCL's remained intact. Furthermore, 43% of PCL's were attenuated at the final evaluation stage and were at risk for late PCL stretch-out. In this series, patients with a deficient or attenuated PCL were treated with an anterior stabilized bearing that could be utilized with a cruciate retaining femoral component. We advocate that a cruciate substituting bearing be routinely available when undertaking a cruciate retaining TKA.

Key words: TKA, CR TKA, PCL, ACL, Anterior Stabilized, Primary

Level of Evidence: AAOS Therapeutic Study Level III

Introduction

Primary total knee arthroplasty (TKA) is a successful procedure for patients suffering from advanced gonarthrosis of the knee [1,11,31,47]. As technology has evolved, several different TKA designs have been utilized. These include the PCL retaining TKA (CR TKA), the posterior stabilized TKA (PS TKA), and the anterior stabilized TKA (AS TKA). The AS TKA is also referred to as an ultra-congruent TKA. Clinical success has been reported with all three knee designs [29,32,33,42,44].

There is still vigorous debate among surgeons on which knee design should be used routinely for primary TKA. Each knee design has distinct merits and drawbacks. Surgeon preference in design selection is

most often based upon his/her prior surgical training and personal experience. A common focus of debate centers on the integrity of the PCL during and after TKA [39,40,41,43,56,57].

Many surgeons feel that the PCL cannot be preserved in a consistent fashion. A number of reasons exist for this line of thinking including knee deformity requiring PCL release, PCL contracture due to the arthritic process requiring release, and PCL damage during surgical technique. These issues cause some surgeons to favor the removal of the PCL with routine conversion to an AS or PS TKA [5,13,14,15,52,54,57]. The literature documents the effects of late knee instability in CR TKA which is

† LA Orthopedic Institute, Los Angeles, CA

thought to be a result of late PCL laxity creating a flexion instability pattern [13]. Flexion instability clinically presents with recurrent knee effusion, activity related pain, the inability to reciprocate stairs, and difficulty arising from a low chair [18,19,23].

The literature provides scant information regarding what happens to the PCL during primary CR TKA. This study was conducted to prospectively examine that fate of the PCL during three stages of the CR TKA procedure. We believe that the PCL is more frequently damaged than what is reported in existing literature.

Materials and Methods

Between October 2007 and October 2012, 368 primary TKA's were performed at a single institution by the senior author (EJM). The surgical technique remained consistent throughout the study period (see Surgical Technique). The assessment of the PCL was performed with the knee at 90° of flexion. The ligament was visually inspected and subjectively palpated. The PCL was assessed during three stages of the TKA procedure. The first evaluation was upon inspection of the knee after initial arthrotomy. During the first evaluation we also assessed the ACL before its removal. The ACL was inspected and rated as being intact, attenuated, or completely deficient. We defined a ligament (ACL or PCL) as "attenuated" when more than 50% of the fibers were deficient or the ligament was felt to be lax by direct palpation. The initial evaluation of the PCL was made after removal of the ACL and all intercondylar osteophytes. The second evaluation was made after completing all femoral and tibial bone cuts, but before knee ligament balancing. The PCL was assessed during this stage with laminar spreaders placed between the femur and tibia at 90° of flexion. The laminar spreaders were opened until complete flexion gap distraction was obtained. The PCL was assessed again as being intact, attenuated, or completely deficient. The third evaluation stage was conducted after knee ligament balancing with components cemented and the final modular tibial bearing placed. At final assessment, the PCL was documented as retained intact, retained attenuated, partially released, or removed. We define the PCL as partially released when more than 50% of the fibers are released from the femoral attachment.

All patients were followed for a minimum of six months. Functional performance was graded us-

ing the Knee Society Score [26]. All charts were reviewed for complications and implant failures. Failure was defined as implant removal or recommended implant removal. A knee complication was defined as any reoperation on the knee where the TKA implants were retained (this includes cases of modular tibial bearing exchange). Medical complications were recorded, but we do not report on these events so as to focus on the results of the surgical technique.

Surgical Technique

All TKA's were preformed using a less invasive paramedical incision with a medial parapatellar arthrotomy [10,30]. The incision was made long enough to allow for comfortable access and exposure to the knee. The Vanguard Total Knee System™ (Biomet, Warsaw, IN) was used in all cases. A cruciate retaining femur was inserted in all cases. Three polyethylene tibial bearing designs were used: a flat design, a dished posterior design, or an anterior stabilized (also known as "ultracongruent") bearing [46]. The anterior stabilized bearing had an extended anterior lip which was of the same height of the Vanguard posterior stabilized post. Additionally, the posterior lip was extended 50% more than the dished tibial insert. The selection of each bearing design depended upon the flexion stability of the knee. An anterior stabilized bearing was used whenever the PCL was deficient or removed.

An intramedullary guide was used to cut the distal femur at a 5° valgus cut angle. Rotation of the femur was based upon the Anterior-Posterior axis as described by Whiteside [58]. Sizing of the femur was measured using a posterior reference technique. The proximal tibial bone cut was made using an extramedullary guide system. A bone block around the PCL was not used. A posterior slope was cut in all cases parallel to the medial compartment slope [6,7,8,9,24,27,28]. Coronal and sagittal plane balancing was performed utilizing a modified spacer block technique. Specifically, a trial femur was inserted along with a tibial trial sans a keel. Rotation of the tibia was set to provide congruent femoral-tibial mating in deep flexion. All patellae were resurfaced with a 3 peg polyethylene reduced thickness implant (Biomet, Warsaw, IN), a subset of implants that are 15% thinner than the standard patellar implant. All implants were cemented using Cobalt cement (Biomet, Warsaw, IN) without antibiotics. All surger-

ies were performed with body exhaust suits (Stryker, Kalamazoo, MI) in non-laminar flow rooms. Anesthesia consisted of a general anesthetic combined with spinal anesthesia with low-dose intrathecal preservative free morphine sulfate (0.1 mg).

Results

The results of the initial ligament assessment are presented in Tables 1 & 4. For the anterior cruciate ligament [2], 15% were judged to be attenuated while 18% were deemed deficient. For the posterior cruciate ligament, 5% were judged to be attenuated and 1% of the ligaments were assessed deficient.

The second assessment stage of the PCL was made after initial bone cuts. These results are listed in Table 2. At this stage, 30% of the PCL's were judged to be attenuated. In most instances, this occurred due to the saw blade cutting the anterolateral bundle of the PCL. After making all bone cuts, 19% of the PCL's had been removed. These ligaments were either com-

pletely cut by the saw blade or removed with the resected proximal tibia.

Tables 2a & 2b are subsets derived from Table 2. Specifically, Table 2a details the fate of the 188 PCL's assessed as intact after the bone cuts were made. In this group 26% were partially released and 9% were removed in order to balance the knee. Table 2b details the fate of the 112 PCL's assessed as attenuated after the bone cuts were made. In this group 5% were partially released and 4% were removed in order to balance the knee.

The results of the final PCL assessment stage are presented in Table 3. Of the 368 TKA cases presented in this study, only 33% maintained completely intact PCL's. A further 28% of PCL's were retained but assessed as attenuated (injured during technique). Lastly, 15% of the PCL's in this series were partially released (for knee balancing) and 24% were removed.

We experienced 29 complications (8%) which are listed in Table 5. The most common complication we encountered was arthrofibrosis requiring manipulation (4%). There were 21 failures (6%) in this series

at a maximum follow-up of 72 months (range 6-72 months). Failures are listed in Table 6. The most common reasons for failure were chronic periprosthetic infection (1.4%) and supracondylar femur fracture (1.4%). Interestingly, we encountered 3 cases (0.8%) of metal hypersensitivity to Nickel. This was based upon the Lymphocyte Transformation Test (LTT) described by Hallab [21,22]. These implants were revised to Nickel-free implants.

Table 1
Stage I: PCL Inspection at Arthroscopy

PCL Initial	N = 368	
Intact	N = 348	94%
Attenuated	N = 17	5%
Deficient	N = 3	1%

Table 2
Stage II: PCL Inspection at Bone Cuts

PCL after Bone Cuts	N = 368	
Intact	N = 188	51%
Attenuated/Damaged	N = 112	30%
Removed	N = 68	19%

Table 2a
Fate of 188 Intact Ligaments at Bone Cuts

188 Intact after Bone Cuts	N = 188	
Retained	N = 123	65%
Partially Released	N = 49	26%
Removed	N = 16	9%

Table 2b
Fate of 112 Attenuated Ligaments at Bone Cuts

112 Attenuated after Bone Cuts	N = 112	
Retained	N = 102	91%
Partially Released	N = 6	5%
Removed	N = 4	4%

Table 3
Stage III: PCL Inspection at Closure

PCL Final Assessment	N = 368	
Retained Intact	N = 123	33%
Retained Attenuated	N = 102	28%
Partially Released	N = 55	15%
Removed	N = 88	24%

Table 4
ACL Inspection at Arthroscopy

ACL	N = 368	
Intact	N = 245	67%
Attenuated	N = 55	15%
Deficient	N = 68	18%

Table 5: Complications

Manipulation for Arthrofibrosis	14
Superficial Wound Split	5
Traumatic Arthroscopy (Fall)	4
Bearing Change for Hyperextension Laxity	2
Lateral Release for Patellar Subluxation	2
Flexion Laxity after Fall (Bearing Change)	1
Hematoma Evacuation	1

Table 6: Failures

PCL Initial	N = 368	
Intact	N = 348	94%
Attenuated	N = 17	5%
Deficient	N = 3	1%

Discussion

The posterior cruciate ligament is the strongest ligament in the knee joint [3,4,55]. The biomechanical importance of the PCL is dictated by its anatomy. The tibial attachment is relatively compact and extra-articular, inserting approximately 1cm below the joint line on the posterior tibial surface. The PCL is the primary restraint to tibial posterior drawer at all angles of knee flexion.

The posterolateral and posteromedial structures of the knee are responsible for posterior knee stability as the knee nears extension. This explains why isolated rupture of the posterior cruciate ligament does not lead to knee instability with walking [20,53]. Additionally, the PCL has a proprioceptive function. Studies using immunohistochemical stains specific for neural tissue demonstrate the presence of mechanoreceptors in the PCL [2,38].

Osteoarthritis of the knee causes disabling pain and affects all knee structures [2]. Contracture and fibrosis of the PCL is part of the arthritic process and may compromise the function of the PCL [59]. For this reason, when performing TKA, surgeons are divided into two main camps when choosing a specific TKA implant system: those who prefer the removal of the PCL and those who favor its preservation. Surgeons who prefer to remove the PCL substitute the ligament with one of two designs. The first option is the posterior stabilized knee. This design has a central tibial polyethylene post which articulates with a femoral cam preventing the femur from dislocating anteriorly in flexion [52,56]. The second option is the anterior stabilized knee. In this design, instead of a central polyethylene post, there is a raised anterior lip of similar height as a posterior stabilized post that resists anterior femoral translation similar to the PS TKA design [45].

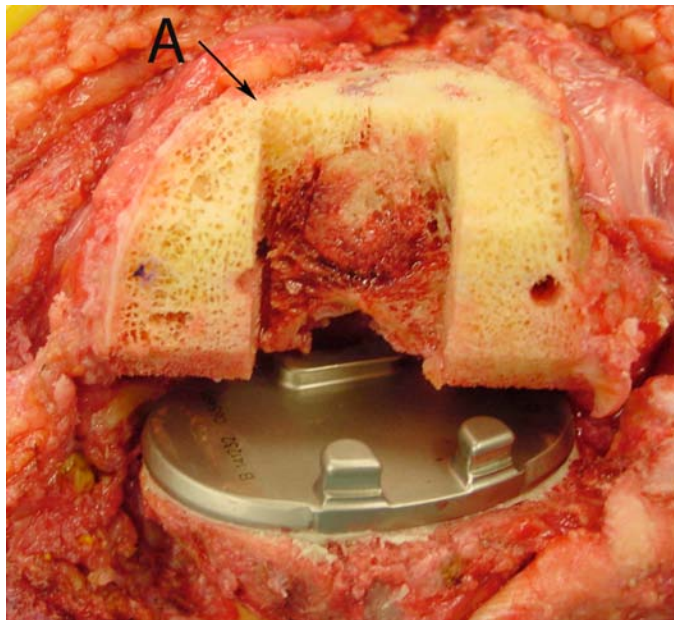


Figure 1

Intra-operative photograph during primary right PS TKA. This photo emphasizes the significant amount of bone that is removed in the middle of the femur to accommodate the femoral box. A wide box cut in a small femur leaves little condylar bone and may cause fracture. Note the area of lateral femoral condyle (A) where fracture may occur.

Surgeons that eschew cruciate sacrificing designs cite several subjective reasons. First, compared to the PS TKA design, the CR TKA is generally felt to be “less noisy.” There tends to be fewer flexion clicks and rattles which can sometimes concern patients. Furthermore, some surgeons are concerned by the amount of bone removed from the intercondylar notch in some PS TKA designs which can be significant. This is especially relevant in small sized femurs (Figure 1) [34]. Additionally, reports suggest an increase in retrocondylar bone density loss in PS TKA systems. The central metallic box bears load centrally which reduces mechanical loads in the femoral condyles [50]. Flexion laxity with complete removal of the PCL is also a concern to surgeons. If the flexion gap is loose, the risk for mid-flexion instability and femoral cam jump is increased [16,17,37].

Retaining the PCL is not as simple as it sounds. First, modern prosthetic designs that focus on high flexion advocate recreating the native posterior slope. This is problematic with Asian-Pacific patients where native slope is reported as high as 10-13° [12]. Cutting the tibial bone at this slope may remove the entire PCL attachment on the tibia. Secondly, less invasive techniques make it difficult to preserve a bone island around the PCL attachment on the tibia. A bone island, while protective of the PCL, limits the amount the tibial component can be rotated. Thus,

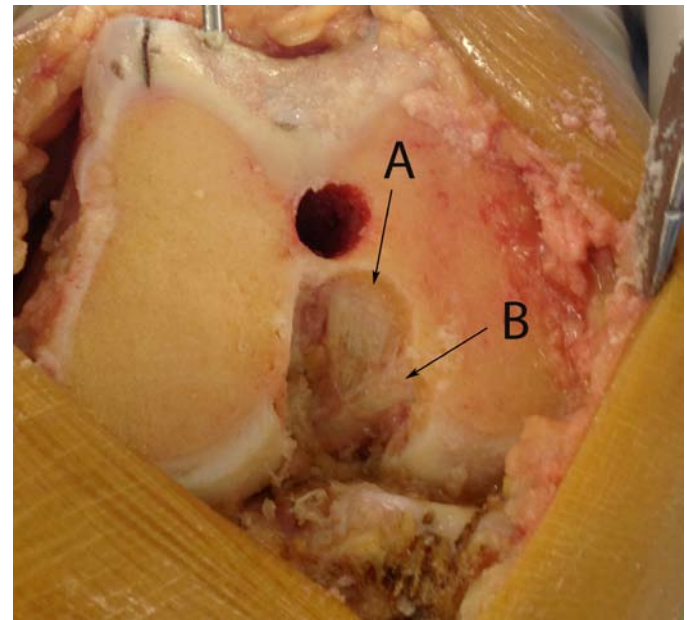


Figure 2

Intra-operative photograph during primary right CR TKA. This photo shows the two distinct bundles of the PCL: the posteromedial (PM) bundle (A) and the anterolateral (AL) bundle (B). Note that the AL bundle is anterior and is the most susceptible to saw cut damage.

many surgeons avoid preserving a bone island to allow for rotation of the tibial component for optimal mating with the femur. Furthermore, the anterolateral bundle of the PCL inserts on the tibia anterior to the posteromedial bundle (Figure 2). This bundle is important in maintaining midflexion stability [4,55].

Knees with significant deformity require more extensive releases, including the PCL. “Balancing” the PCL in flexion with releases either off the femur or tibia can significantly compromise the integrity of the ligament [48,51]. For all of these reasons, a weakened PCL is of concern. A CR TKA with a significantly weakened PCL is at risk for late flexion instability as the damaged ligament can stretch out over time.

This study provides a humbling review of the status of the PCL when using a CR TKA design. First we describe that 6% of PCL’s are either attenuated or deficient at initial presentation. This incidence of attenuated PCL’s is in accordance with the literature [2,5,46]. This is an important observation considering that many surgeons exclusively use CR TKA designs. Surgeons should be ready to substitute for the attenuated/deficient PCL when using a CR TKA system.

We also documented that 33% of ACL’s are either attenuated or deficient at initial presentation. This observation is not novel, but the data reinforces the concept that many knees which become arthritic may be caused by traumatic ligament injuries. This has significant bearing to knee arthroplasty. First, a mobile bearing unicompartment knee arthroplasty is absolutely contraindicated when the ACL is deficient. Furthermore, there are currently two TKA designs soon to be introduced that preserve both the PCL and ACL (Biomet, Warsaw, IN & Wright, Arlington, TN). Based on this data, an ACL/PCL preserving TKA design could not be used routinely in clinical practice.

In the second evaluation stage, after all bone cuts were made, only 51% of the PCL’s remained intact. There are two main reasons to explain our high rate of PCL damage. First, our surgical technique focused on a high flexion protocol. This was dictated by our city’s cultural diversity (Los Angeles, CA) and our relative proximity to the Pacific Rim countries where knee flexion is highly valued. Our standard TKA protocol included cutting the tibia with a native posterior slope [36,60]. With the removal of posterior tibial bone, a significant amount of the PCL inserted into the proximal tibia was removed, weakening the PCL

or removing it altogether. Furthermore, we did not use a preserving bone block around the tibial PCL insertion. Our priority was to optimize tibial component rotation with congruent implant mating into deep flexion. Prior to this study, we observed that preserving a bone island around the PCL impeded optimal tibial component mating with the femur. The PCL’s damaged or removed in this phase of the TKA procedure were based solely on mechanical bone cuts. Altering surgical technique in this phase may mitigate the incidence of PCL damage, but the surgeon must be willing to accept the trade off. In our opinion, decreasing posterior slope and limiting tibial component rotation with a protective PCL bone block may limit flexion range and may cause kinematic dysfunction with sub-optimal femoral-tibial mating [40,49].

In the third evaluation stage, after knee balancing was complete and all implants were in place, only 33% of PCL’s remained intact. In 43% of our TKA’s the PCL was judged to be attenuated either by mechanical damage or surgeon release for knee balancing. This latter group, in our opinion, is at risk for late flexion and/or midflexion instability. As time progresses, the attenuated PCL can be further damaged by several mechanisms. These include manipulation for arthrofibrosis, osteolysis, trauma (i.e., falls), and PCL stretch out with arduous functional activities. We feel strongly that this group should be treated with a cruciate substituting design. In this study, our solution was to insert an anterior stabilized bearing. For us, this was a simple intra-operative conversion as the AS bearing mates with the CR femur. The anterior stabilized bearing obviates the need to change to a posterior stabilized knee system in the middle of the TKA procedure, saving valuable OR time [45].

Lastly, in our final evaluation, 24% of PCL’s were completely lost either by mechanical damage or surgeon release for balancing. This group was treated with a cruciate substituting design which again utilized an anterior stabilized bearing. We observed in this study that the anterior stabilized bearing provided acceptable function and stability across a wide variety of clinical deformities. Thus, we do not feel the need to convert to a posterior stabilized design.

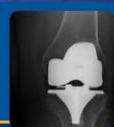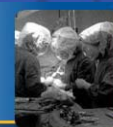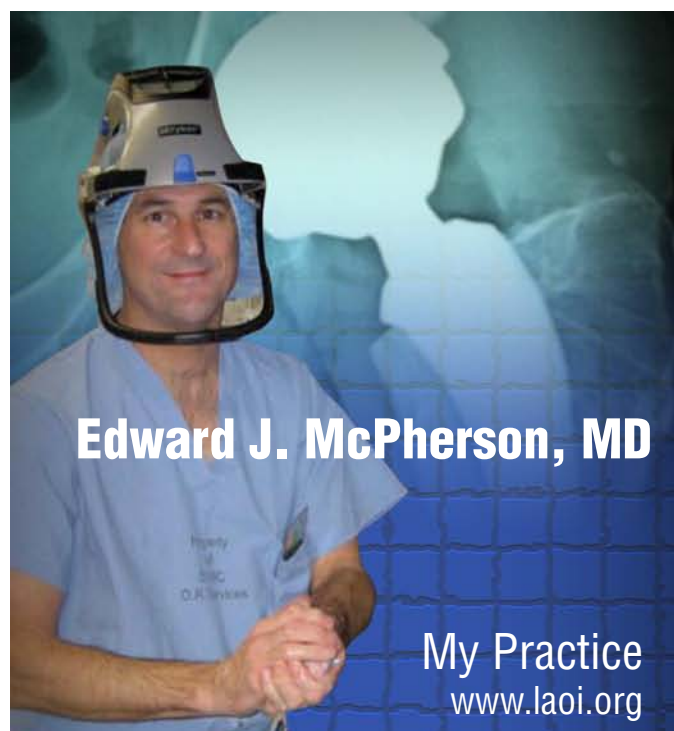
Complete preservation of the PCL during primary TKA is difficult. Only one third of the PCL’s in this series remained completely intact. We advocate that a cruciate substituting bearing be routinely available when using a CR TKA. Furthermore, 40% of our PCL’s were attenuated for this group. We encourage

the use of a PCL substituting bearing as this group is potentially at risk for late term flexion and/or mid-flexion instability.

References

- Abdel MP, Morrey ME, Jensen MR. Increased long-term survival of posterior cruciate-retaining versus posterior cruciate-stabilizing total knee replacement. *J Bone Joint Surg (Am)*. 2011; 93(22): 2072-8.
- Albert A, Feoli F. Are lesions of the posterior cruciate ligament predictable before knee arthroplasty? A histological study of 434 ligaments in osteoarthritic knees. *Acta Orthop Belg*. 2008; 74: 652-8.
- Amis AA, Bull AM, Gupte CM. Biomechanics of the PCL and related structures: posterolateral, posteromedial and meniscomfemoral ligaments. *Knee Surg Sports Traumatol Arthrosc*. 2003; 11(5): 271-81.
- Amis AA, Gupte CM, Bull AM. Anatomy of the posterior cruciate ligament and the meniscomfemoral ligaments. *Knee Surg Sports Traumatol Arthrosc*. 2006; 14(3): 257-63.
- Arbuthnot JE, Wainwright O, McNicholas MJ. Dysfunction of the posterior cruciate ligament in the total knee arthroplasty. *Knee Surg Sports Traumatol Arthrosc*. 2001; 19: 893-8.
- Argenson JN, Komistek RD, Mahfouz M, et al. A high flexion total knee arthroplasty design replicates healthy knee motion. *Clin Orthop*. 2004; 428: 174-9.
- Argenson JN, Scuderri GR, Komistek RD, et al. In vivo kinematic evaluation and design considerations related to high flexion in total knee arthroplasty. *J Biomechanics*. 2005; 38: 277-84.
- Bellemans J, Banks S, Victor J, et al. A fluoroscopic analysis of the kinematics of deep flexion in total knee arthroplasty. Influence of posterior condylar offset. *J Bone Joint Surg*. 2002; 84B: 50-3.
- Bellemans J, Robijns F, Duerinckx J. The influence of tibial slope on maximal flexion after total knee arthroplasty. *Knee Surgery Sports Traumatol Arthrosc*. 2005; 13(3): 193-6.
- Bonutti PM, Mont MA, McMahon M. Minimally Invasive Total Knee Arthroplasty. *J Bone Joint Surg (Am)*. 2004; 86: 26-32.
- Callaghan JJ, Beckert MW, Hennessy DW. Durability of a cruciate-retaining TKA with modular tibial trays at 20 years. *Clin Orthop Relat Res*. 2012; 471: 109-17.
- Chiu KY, Tang WM, Yau WP. Review article: Knee Flexion after Total Knee Arthroplasty. *Journal of Orthopaedic Surgery*. 2002; 10(2): 194-202.
- Chouteau J, Lerat JL, Testa R. Sagittal laxity after posterior cruciate ligament-retaining mobile-bearing total knee arthroplasty. *J Arthroplasty*. 2009; 24(5): 710-5.
- Christen B, Heester beek PV, Wymenga A. Posterior Cruciate Ligament Balancing in Total Knee Replacement, the quantitative relationship between tightness of the flexion gap and tibial translation. *J Bone Joint Surg (Br)*. 2007; 89-B: 1046-50.
- Conditt MA, Noble PC, Bertolusso R. The PCL significantly affects the functional outcome of Total Knee Arthroplasty. *J Arthroplasty*. 2004; 19: 107-12.
- Cormie MJ, Siston RA, Giori NJ. Posterior Cruciate Ligament Removal Contributes to Abnormal Knee Motion During Posterior Stabilized Total Knee Arthroplasty. *Journal of Orthopaedic Research*. 2008; 26(11): 1494-99.
- Dennis DA, Komistek RD, Colwell CE Jr. In vivo anteroposterior femoral translation of Total Knee arthroplasty: a multicenter analysis. *Clin Orthop Relat Res*. 1998; 356: 47-57.
- Ermodi GJ, Callaghan JJ. Posterior Cruciate Ligament function following Total Knee Arthroplasty: the effect of joint line elevation. *The Iowa Orthopaedic Journal*. 1999; 19: 82-92.
- Fitz W, Minas T, Sodha S. Dose a modified gap-balancing technique result in medial-pivot knee kinematics in cruciate-retaining Total Knee Arthroplasty? Pilot study. *Clin Orthop Relat Res*. 2012; 470: 91-8.
- Grood ES, Stowers SF, Noyes FR. Limits of movement in the human knee, effect of sectioning the Posterior Cruciate Ligament and posterolateral structures. *JBJS (Am)*. 1988; 70-A: 88-97.
- Hallab NJ, Mikecz K, Jacobs JJ. A triple assay technique for the evaluation of Metal-induced, delayed type hypersensitivity response in patients with or receiving total joint arthroplasty. *Journal of Biomedical Materials Research*. 2000; 53: 480-9.
- Hallab NJ. Metal sensitivity in patients with orthopaedic implants. *Journal of Clinical Rheumatology*. 2001; 7: 215-8.
- Heesterbeek P, Keijsers N, Wymenga A. Posterior Cruciate Ligament affects antero-posterior translation during flexion gap distraction in Total Knee Replacement. An intraoperative study involving 50 patients. *Acta Orthop*. 2010; 81(4): 471-77.
- Huang HT, Su JY, Wang GJ, et al. The early results of high flexion total knee arthroplasty. A minimum of 2 years follow-up. *J Arthroplasty*. 2005; 20(5): 674-9.
- In Y, Kim JM, Woo YK. Factors affecting flexion Gap tightness in cruciate retaining total knee arthroplasty. *J Arthroplasty*. 2009; 24(2): 317-21.
- Insall JN, Dorr LD, Scott WN. Rational of the Knee Society Clinical Rating System. *Clin Orthop Relat Res*. 1989; 248: 13-4.
- Jojima H, Whiteside LA, Ogata K. Effect of tibial slope or posterior cruciate ligament release on knee kinematics. *Clin Orthop Relat Res*. 2004; 426: 194-8.
- Kim YH, Sohn KS, Kim JS. Range of motion of standard and high flexion posterior stabilized total knee prostheses. *J Bone Joint Surg*. 2005; 87(7): 1470-5.
- Kubiak P, Archibeck MJ, White RE Jr. Cruciate-Retaining total knee arthroplasty in patients with at least fifteen degrees of coronal plane deformity. *J Arthroplasty*. 2008; 23(3): 366-70.
- Laskin RS, Beksac B, Pittors K. Minimally Invasive Total Knee Replacement through a mini-midvastus incision: An Outcome Study. *Clin Orthop Relat Res*. 2004; 428: 74-81.
- Laskin RS. The Insall Award. Total Knee Replacement with posterior cruciate ligament retention in patients with a fixed varus deformity. *Clin Orthop Relat Res*. 1996; 331: 29-34.
- Lattanzio PJ, Chess DG, MacDermid JC. Effect of posterior cruciate ligament in knee arthroplasty. *J Arthroplasty*. 1998; 13(5): 580-5.
- Lombardi AV Jr, Berend KR. Posterior Cruciate Ligament retaining, posterior stabilized, and varus/valgus posterior stabilized constrained articulations in total knee arthroplasty. *Instr course lect*. 2006; 55: 419-27.
- Lombardi AV Jr, Mallory TH, Waterman RA, Eberle RW. Intercondylar distal femoral fracture. An unreported complication of posterior-stabilized total knee arthroplasty. *J Arthroplasty*. 1995; 10(5): 643-50.
- Mahoney OM, Noble PC, Rhoads DD. Posterior Cruciate Function following Total Knee Arthroplasty. A biomechanical study. *J Arthroplasty*. 1994; 9(6): 569-78.
- Massin P, Gournay A. Optimization of the posterior condylar offset, tibial slope, and condylar roll-back in total knee arthroplasty. *J Arthroplasty*. 2006; 21(6): 889-96.
- McPherson EJ, Cuckler J, Lombardi AV. Midflexion Instability in Revision Total Knee Arthroplasty. *Surg Technol Int*. 2008; 17: 249-52.
- Mihalko WM, Creek AT, Komatsu DE. Mechanoreceptors found in a posterior cruciate ligament from a well functioning Total Knee Arthroplasty retrieval. *J Arthroplasty*. 2011; 26(3): 504.e9-504.e12.
- Misra AN, Hussain MR, Fiddian NJ. The role of the posterior cruciate ligament in Total Knee Replacement. *J Bone Joint Surg*. 2003; 85-B: 389-92.
- Most E, Zayontz S, Rubash HE. Femoral roll back after cruciate retaining and stabilizing total knee arthroplasty. *Clin Orthop Relat Res*. 2003; 410: 101-13.

41. Nelissen RG, Hogendoorn PC. Retain or Sacrifice the posterior cruciate ligament in total knee arthroplasty? A histological study of the cruciate ligament in osteoarthritic and rheumatoid disease. *J Clin Pathol.* 2001; 54: 381-4.
42. Nelson CL. Total Knee Arthroplasty with preservation of the posterior cruciate ligament. *The University of Pennsylvania Orthopaedic Journal.* 1999; 12: 96-100.
43. Pagnano MW, Hanssen AD, Lewallen DG. Flexion instability after primary posterior cruciate retaining total knee arthroplasty. *Clin Orthop Relat Res.* 1998; 356: 39-46.
44. Parsley BS, Conditt MA, Bertolusso R. Posterior Cruciate Ligament Substitution is not essential for excellent postoperative outcome in Total Knee Arthroplasty. *J Arthroplasty.* 2006; 21: 127-31.
45. Peters CL, Mulkey P, Erickson J. Comparison of Total Knee Arthroplasty with Highly Congruent Anterior Stabilized Bearings versus a Cruciate-retaining Design. *Clin Ortho Relat Res.* 2013;1528-1132. Available from: Springer-Verlag, New York, NY. Accessed July 15, 2013.
46. Pinskerova V, Johal P, Williams A. Does the femur roll-back with flexion? *J Bone Joint Surg (Br).* 2004; 86-B: 925-31.
47. Ritter AM, Berend ME, Faris PM. Long term follow-up of anatomic graduated components posterior cruciate-retaining total knee replacement, 15 years 98% survival. *Clin Orthop Relat Res.* 2001; 388: 51-7.
48. Ritter MA, Davis KE, Farris A. The role of the Posterior Cruciate Ligament in total knee replacement. *Bone and joint research.* 2012; 1(4): 64-70.
49. Ritter MA, Harty LD, Davis KE, et al. Predicting range of motion after total knee arthroplasty. *JBJS (Am).* 2003; 85-A(7): 1278-85.
50. Saari T, Uvehammer J, Carlsson LV. Posterior Stabilized Component increased femoral bone loss after total knee replacement. 5 years follow up of 47 knees using dual energy X-ray absorptiometry. *Knee.* 2006; 13(6): 435-9.
51. Scott RD, Chmell MJ. Balancing the Posterior Cruciate Ligament during cruciate-retaining fixed and mobile bearing total knee arthroplasty: description of the pull-out lift-off and slide-back tests. *J Arthroplasty.* 2008; 23(4): 605-8.
52. Scuderi GR, Pagnano MW. Review article: The rationale for posterior cruciate substituting total knee arthroplasty. *Journal of Orthopaedic Surgery.* 2001; 9(2): 81-8.
53. Stiehl JB, Komistek RD, Dennis DA. A novel approach to knee kinematics. *Am J Orthop.* 2001; 30(4): 287-93.
54. Straw R, Kulkarni S, Attfield S. Posterior Cruciate Ligament at Total Knee Replacement. *J Bone Joint Surg (Br).* 2003; 85-B: 671-4.
55. Tajima G, Ingham SJM, Nozaki M. Morphology of the tibial insertion of the posterior cruciate ligament. *J Bone Joint Surg (Am).* 2009; 91: 859-66.
56. Tanzer M, Smith K, Burnett S. Posterior-Stabilized versus Cruciate Retaining Total Knee Arthroplasty. *J Arthroplasty.* 2002; 17(7): 813-9.
57. Victor J, Banks S, Bellemans J. Kinematics of posterior cruciate ligament retaining and substituting Total Knee Arthroplasty, a positive randomized outcome study. *J Bone Joint Surg (Br).* 2005; 87-B: 646-55.
58. Whiteside LA, Arima J. The Anteroposterior axis for femoral rotational alignment in valgus total knee arthroplasty. *Clin Orthop Relat Res.* 1995; 321: 168-72.
59. Williams RJ 3rd, Westrich GH, Siegel J. Arthroscopic release of the posterior cruciate ligament for stiff total knee arthroplasty. *Clin Orthop Relat Res.* 1996; 331: 185-91.
60. Zelle J, Van der Zanden AC, De Waal Malefijt M. Biomechanical analysis of posterior Cruciate ligament retaining high-flexion Total Knee Arthroplasty. *Clin Biomech.* 2009; 24(10): 842-9.



My Research Facility
www.jisrf.org



Joint Implant Surgery
& Research Foundation



My Medical Center
www.stvincentmedicalcenter.com



As an Orthopaedic surgeon in Los Angeles, CA, I'm grateful to practice medicine in an area with exceptional healthcare. My choice is to practice at St. Vincent Medical Center. My research is in collaboration with JISRF, Founded here in L.A. in 1971 by Prof. Charles O. Bechtol, MD.